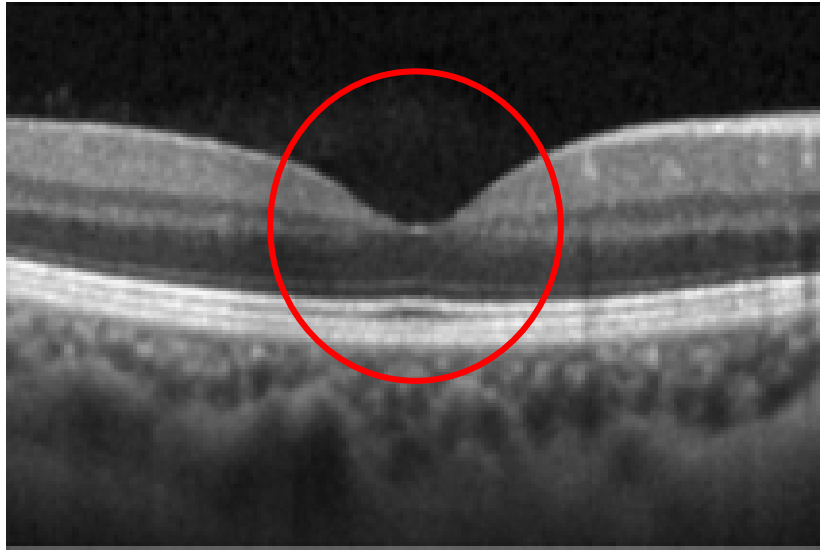


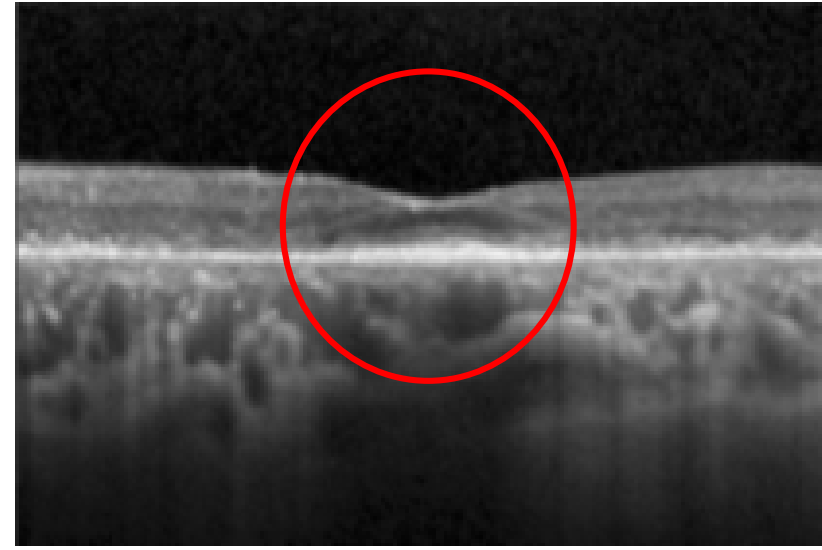
# VISION LOSS DUE TO HCQ or CQ

The pictures below are photos obtained using the new technology that will be used in this research project

**A. Normal Eye**



**B. Severely Damaged Eye**



**Reference:**

Images modified from: Melles RB, Marmor MF. The Risk of Toxic Retinopathy in Patients on Long-term Hydroxychloroquine Therapy. *JAMA Ophthalmol.* 2014;132(12):1453-1460